

Implant Placement Following Socket Preservation with OSSIX™ Bone

OSSIX Bone is a resorbable sponge-like matrix of hydroxyapatite and collagen cross-linked by sugar. Developed to augment hard tissue in periodontal and implant surgeries, it is powered by GLYMATRIX® technology


OSSIX Bone is available in 3 sizes.

OSSIX Bone is currently available in the USA, Europe, Canada, Israel, Chile, and Hong Kong.

datum dental



www.ossixdental.com



OSSIX™ Bone

Implant Placement Following Socket Preservation with OSSIX Bone

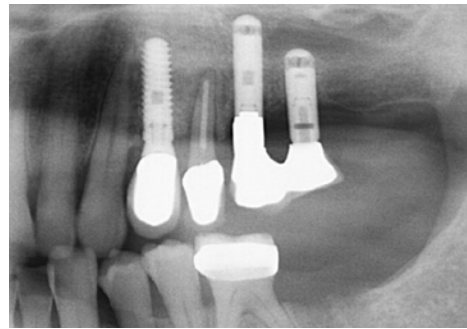
Dr. Yuval Zubery, DMD, Periodontist, Ramat-Hasharon, Israel

datum dental

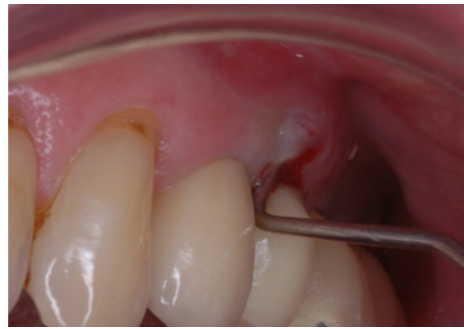
Case background

64 year old male with a non contributory medical history presented for evaluation and treatment of left maxillary premolar. Intra oral examination revealed left maxillary second premolar with a buccal abscess and Cl.II mobility, probing to the apex on the buccal aspect. The radiograph revealed PDL widening. Following extraction, all granulation tissue was removed. The defect was grafted with OSSIX™ Bone collagen sponge soaked with patient's blood (5X5X5mm) and secured with tension-free sutures. OSSIX Bone was left exposed to the oral cavity (The patient received antibiotic coverage - Amoxicillin 15 gr/day for 7 days).

Pre-op

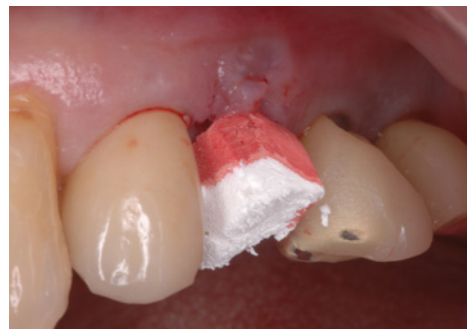

left maxillary premolar – X-ray revealed PDL widening

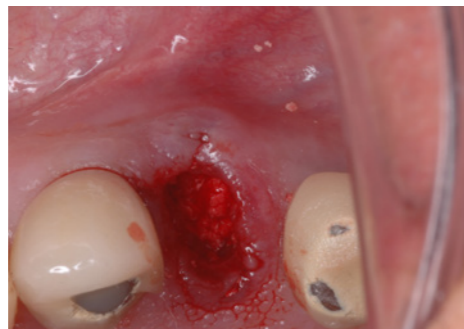

Buccal view revealed buccal abscess and Class II mobility, probing to the apex on the buccal aspect

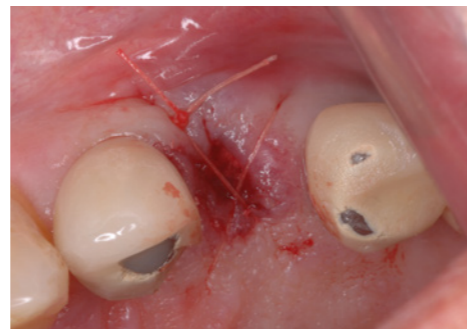Procedure



Hydrating OSSIX Bone with patient's blood, until fully soaked



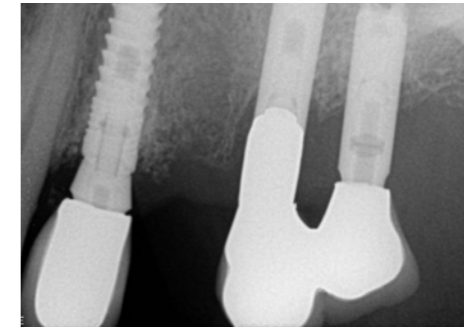
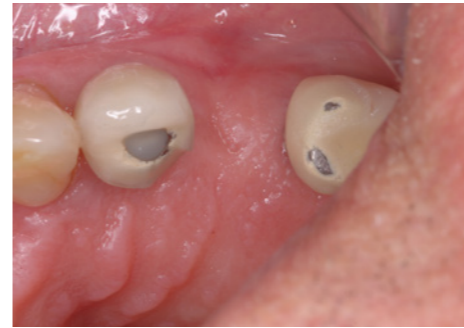Position OSSIX Bone level with the original bone crest



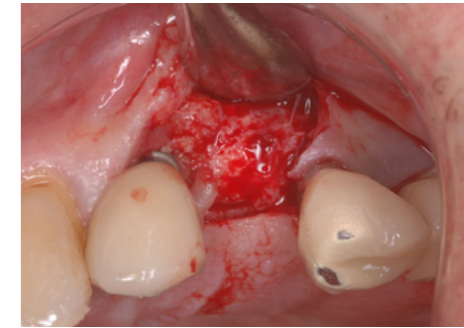
Suturing over with minimal tension

Post-op

Occlusal view at 3.5 months post-op reveals complete healing.

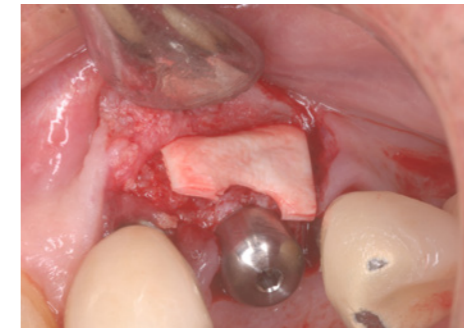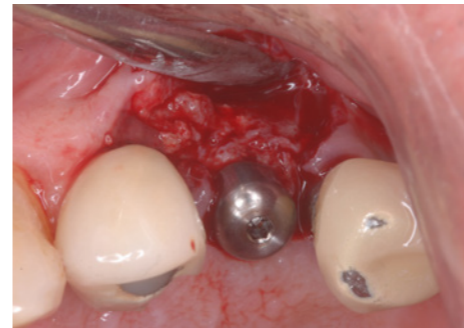


In radiographs: radio opaque material in extraction socket

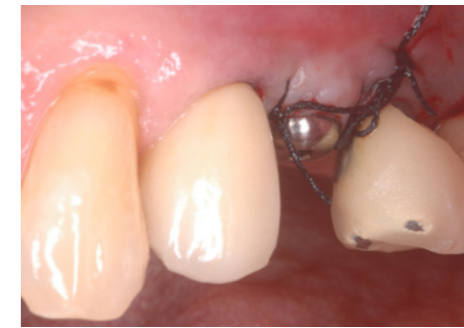

Occlusal view of regenerated ridge at the time of implant placement. Note significant increase in ridge width beyond the confines of the alveolar housing

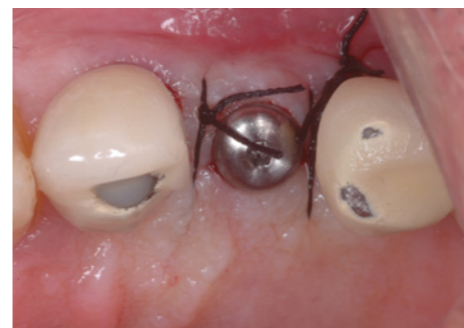Implant placement



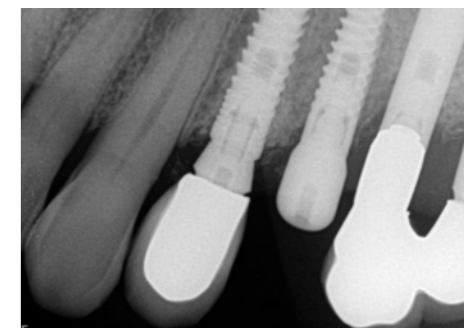
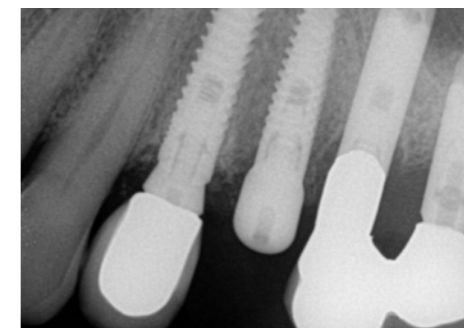
Occlusal view following implant placement. Ossix Volumax is placed on the buccal side



Buccal & Occlusal view of regenerated ridge at the time of implant placement



Immediate post-implant placement radiograph



4.5 months post-implant placement